

PATIENT

Poncho Owczarski

SPECIES

Canine

BREED

Chihuahua Mix

SEX

MN

AGE

11 y

WEIGHT

12.44 lb

INTERPRETED BY

Keith Blass, DVM, MS
DACVIM(Cardiology)

HOSPITAL NAME

Mass Veterinary Services

REFERRING VET

Dr. Masloski

INVOICE

DATE

12/16/21

PRESENTING CLINICAL SIGNS

History of stage B2 degenerative valve disease and mild PH. Doing well. Receiving pimobendan 1.875 mg BID and enalapril 2.5 mg BID.

ECHOCARDIOGRAPHIC FINDINGS

2D, M-mode, and Doppler study.

There is moderate left atrial dilation. The mitral valve leaflets are thickened and exhibit systolic prolapse. A moderate to severe jet of eccentric mitral regurgitation is present. There is moderate left ventricular dilation. Left ventricular systolic function is hyperdynamic. The aorta and aortic appear normal, though trace aortic insufficiency is present. Right atrial and right ventricular dimensions are normal. The tricuspid valve leaflets are mildly thickened, and a mild jet of tricuspid regurgitation is present. TR velocity is consistent with the presence of mild pulmonary hypertension (PG 45 mmHg). The pulmonary artery and pulmonic valve are normal. No heartworms are visualized. No pericardial effusion or cardiac masses are seen.

LA - 33.4 mm
 LVIDd - 36.8 mm
 LVIDs - 16.5 mm
 FS - 55%
 RA - 21.2 mm
 LVOT - 1.67 m/s
 RVOT - 0.92 m/s
 TR - 3.37 m/s

INTERPRETATION OF THE FINDINGS & FURTHER RECOMMENDATIONS

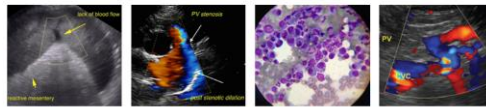
Degenerative mitral and tricuspid valve disease
 Pulmonary hypertension

Poncho's mitral valve disease is similar to what it was in January, as he again has moderate dilation of both his left atrium and left ventricle. As such, Poncho's risk for the development of clinical signs secondary to his disease has not increased, however, given the continued presence of moderate left atrial dilation, careful monitoring for the development of a cough, exercise intolerance, syncope, and labored breathing is still recommended.

Poncho's tricuspid valve disease is still mild and well-compensated. His pulmonary hypertension has progressed mildly, however, it is still considered to be mild in severity.

No change in therapy is recommended based on this exam.

A recheck echocardiogram is recommended in 6 months to monitor for disease progression. Thoracic radiographs are recommended if Poncho experiences respiratory clinical signs.



PATIENT

Poncho Owczarski

SPECIES

Canine

BREED

Chihuahua Mix

SEX

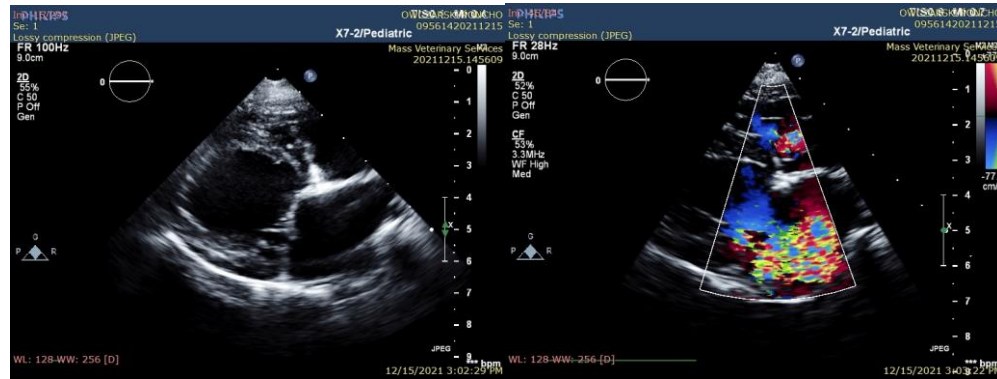
MN

AGE

11 y

WEIGHT

12.44 lb



SEX

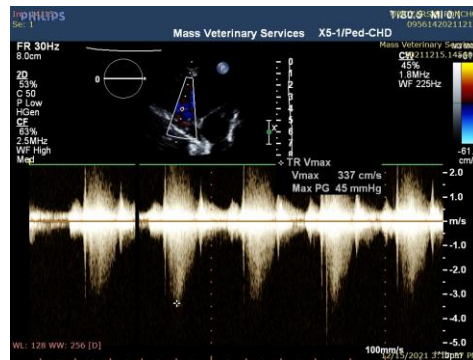
MN

AGE

11 y

WEIGHT

12.44 lb



INTERPRETED BY

Keith Blass, DVM, MS
 DACVIM(Cardiology)

The information and recommendations provided are based on the images presented by the referring veterinarian. No evaluation can be communicated regarding pathology that was not visible in the image/video clips provided.

HOSPITAL NAME

Mass Veterinary
 Services

Thank you for this referral. If the clinical or image interpretation does not parallel your findings or if I can be of any further assistance please contact me.

REFERRING VET

Dr. Masloski

Keith Blass, DVM, MS, DACVIM (Cardiology)

INVOICE

KeithBlass@gmail.com

631-804-5754

DATE

12/16/21